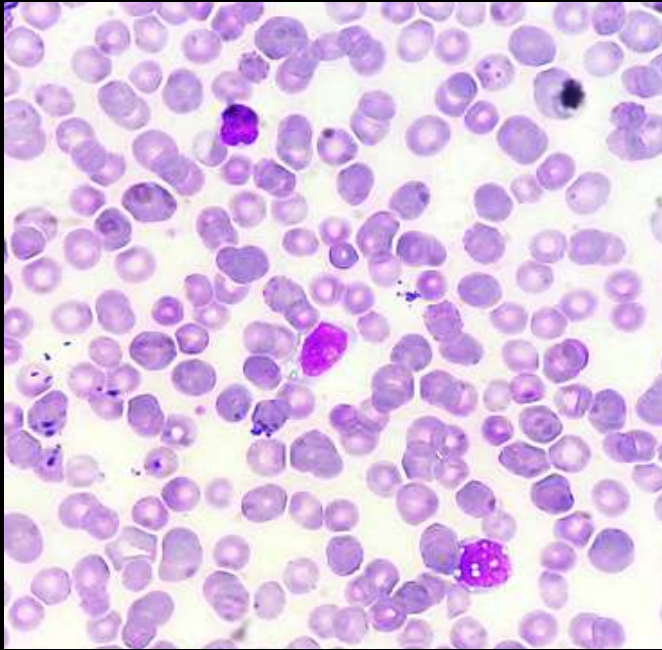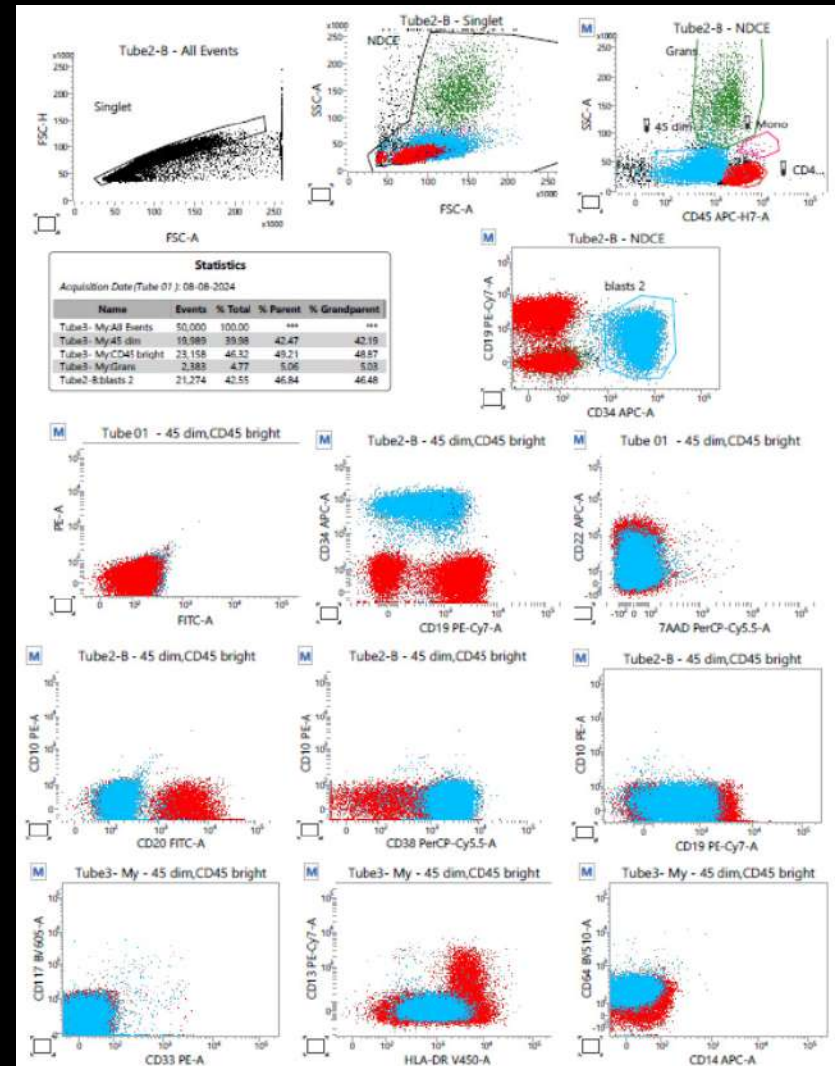


Peripheral smear showed two abnormal population cells: 1) Small to medium sized cells having nuclear cleft, reticular chromatin, scant cytoplasm; 2) Blastoid cells with high N:C ratio, coarse chromatin, 0 to 1 prominent nucleoli and moderate cytoplasm with few vacuoles. (Wright-giemsa stain 100x objective)



Immunophenotyping reveals two abnormal population CD45 dim(blue colour) and in CD45 bright (red colour) region.