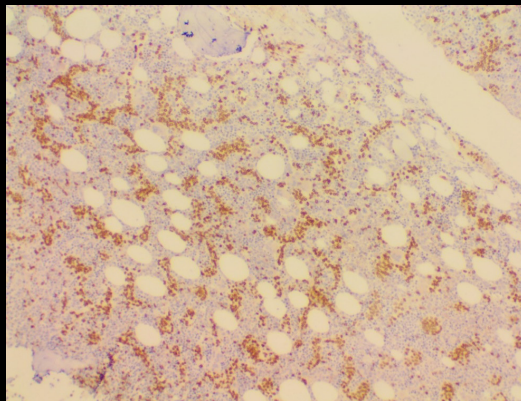


**IMMUNOHISTOCHEMISTRY FINDINGS:**

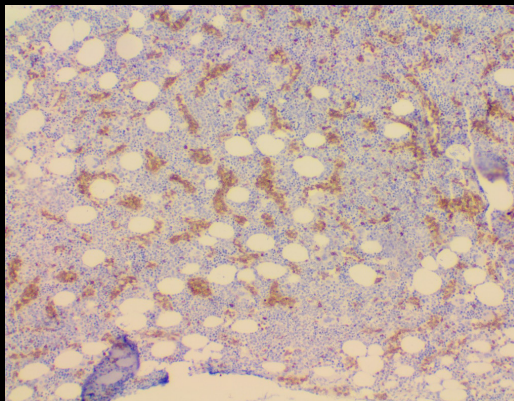
IHC was done for further characterization. The neoplastic cells expressed CD3, CD7, BCL2, CD2, TIA 1 and were negative for CD5, CD4 and CD8, CD20, Perforin, CD56, CD57, Granzyme and TdT.

CD57: Negative in neoplastic cells Perforin: Negative in neoplastic cells

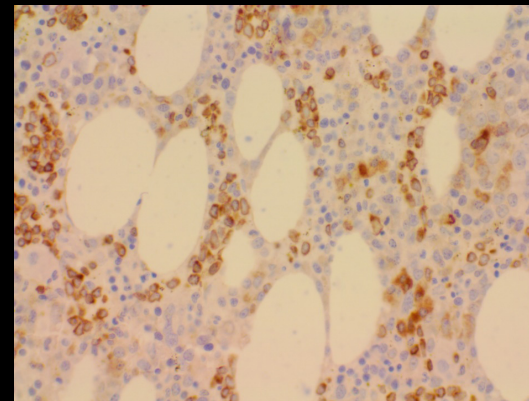
CD5: Negative in neoplastic cells, positive in scattered interstitial lymphocytes



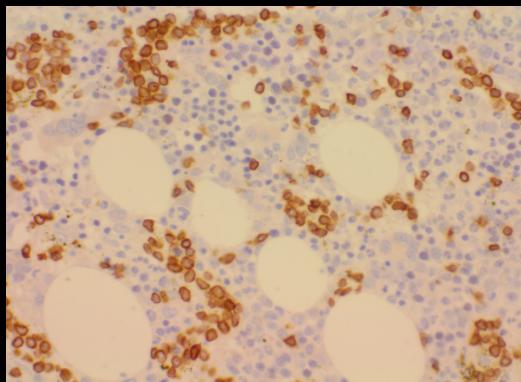
CD3



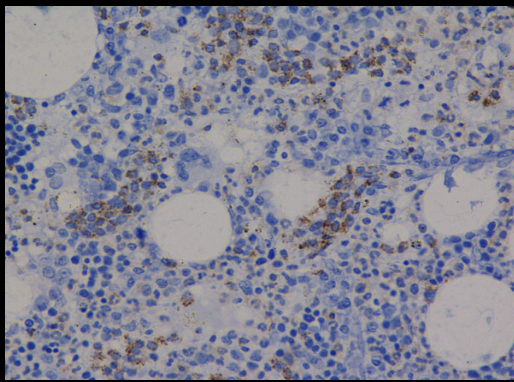
CD7



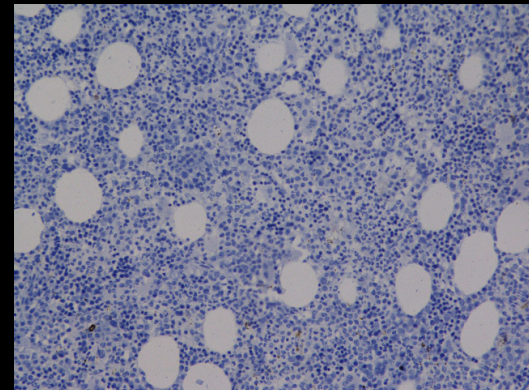
BCL-2



CD2



TIA1



CD 57