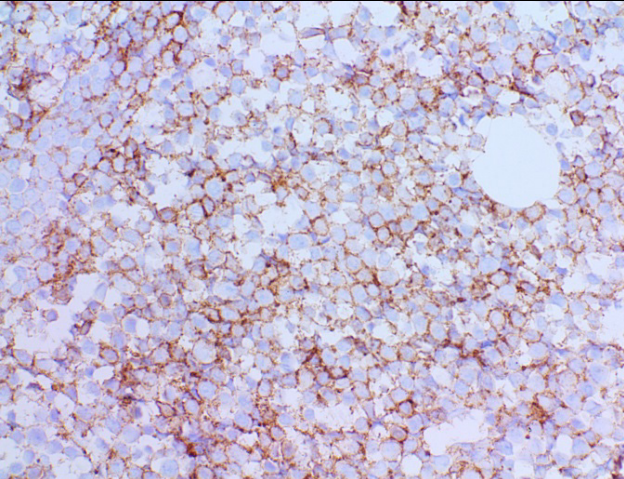
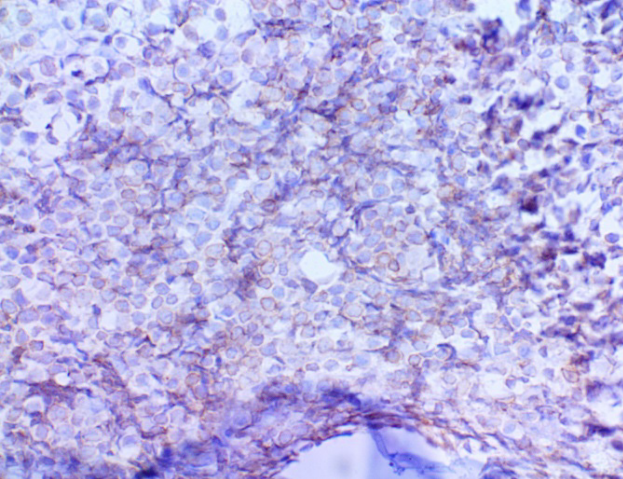


IHC was done for further characterization

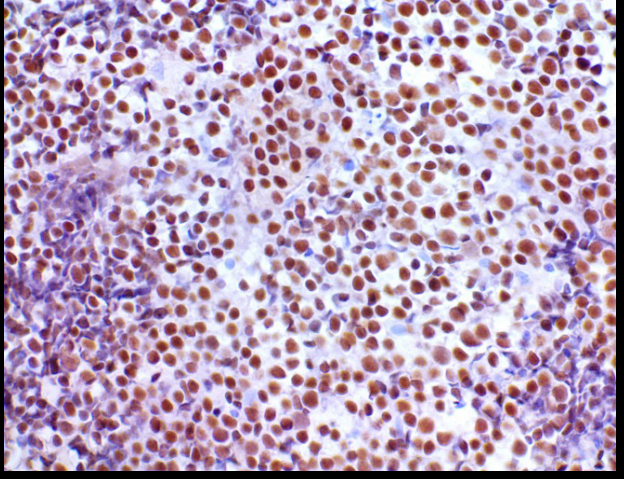
The atypical cells expressed CD19, CD79a, PAX5, CD10, BCL2, BCL6, cMYC with proliferation index of 60-70% (ki 67) and were negative for CD20, CD34, TdT.



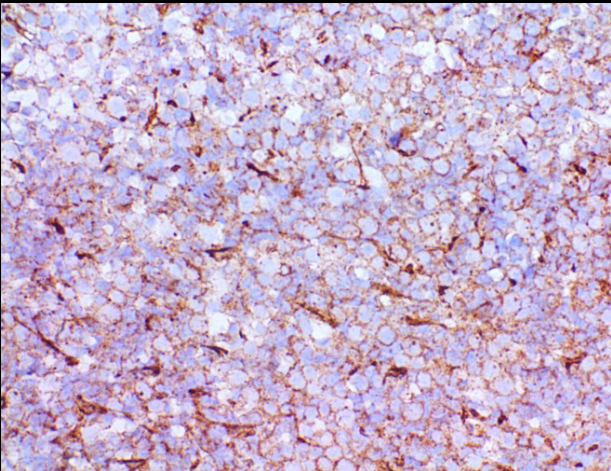
CD19



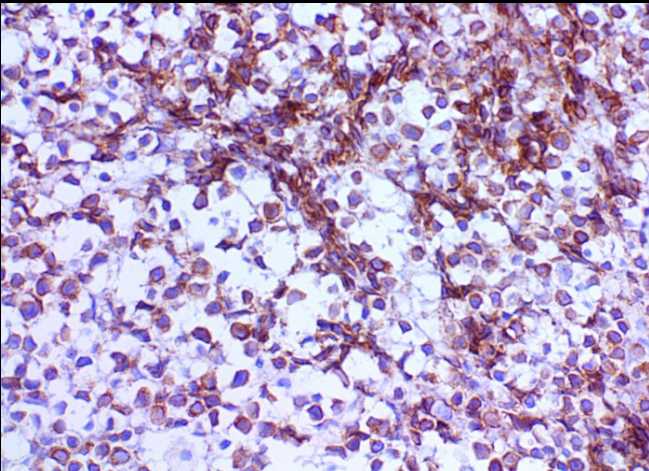
CD79a



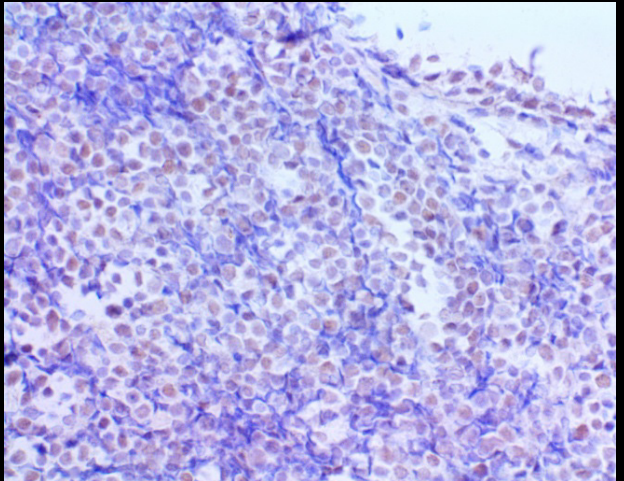
PAX5



CD10



BCL2



BCL6