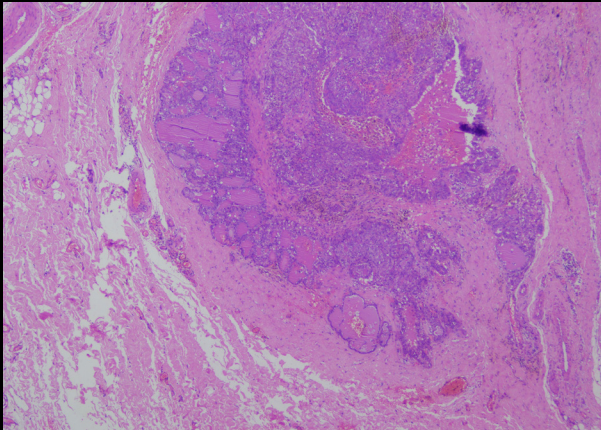


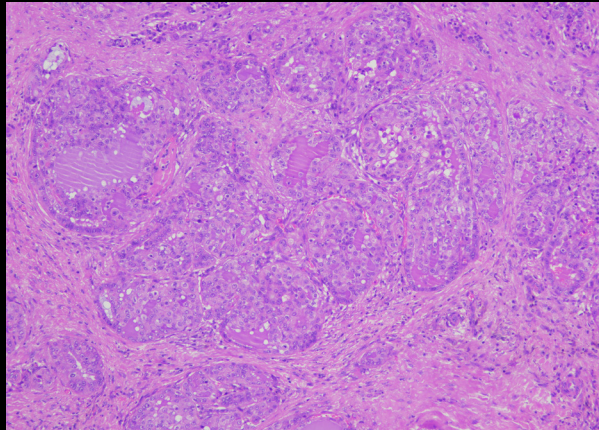
4. H3 K27Me3 – For MPNST
5. SS18-SSX- for Synovial Sarcoma
6. H3 K27M: for high grade diffuse midline gliomas

HISTOLOGIC EVALUATION:

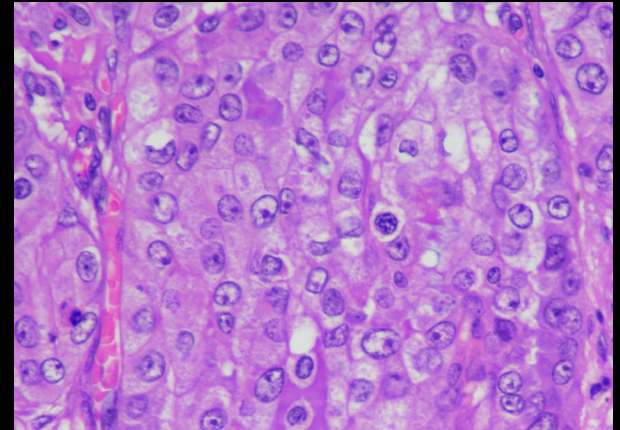
H&E stained section from the single block submitted for review showed lobulated tumor composed of polygonal cells with granular amphophilic to eosinophilic cytoplasm having papillary cystic and solid architecture (Fig 1,2). A few tumor cells showed vacuolated cytoplasm. No significant mitotic activity (0-1/10 hpf), high grade nuclear features or perineural invasion was seen (Fig 3). A diagnosis of acinic cell carcinoma was proposed at this stage and IHC was advised.



(Fig1 he 4x)



(Fig2 he 10x b)



(Fig3 he 40x)