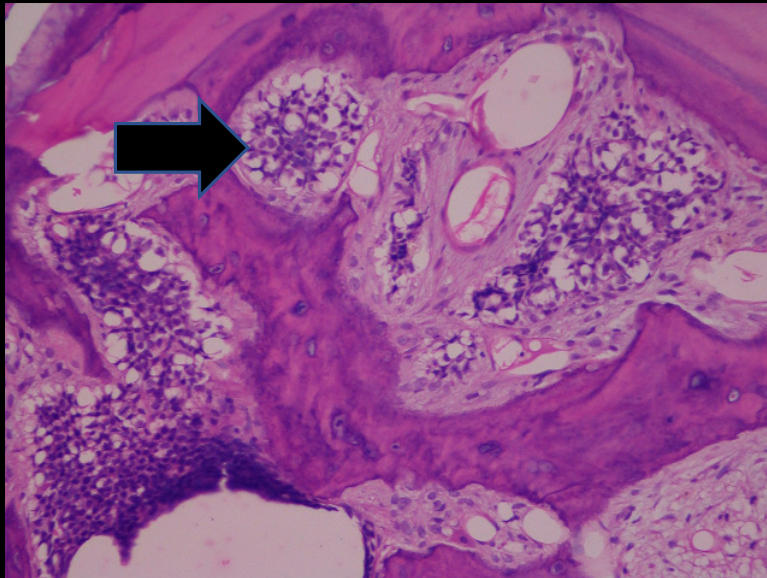


BONE MARROW BIOPSY FINDINGS:

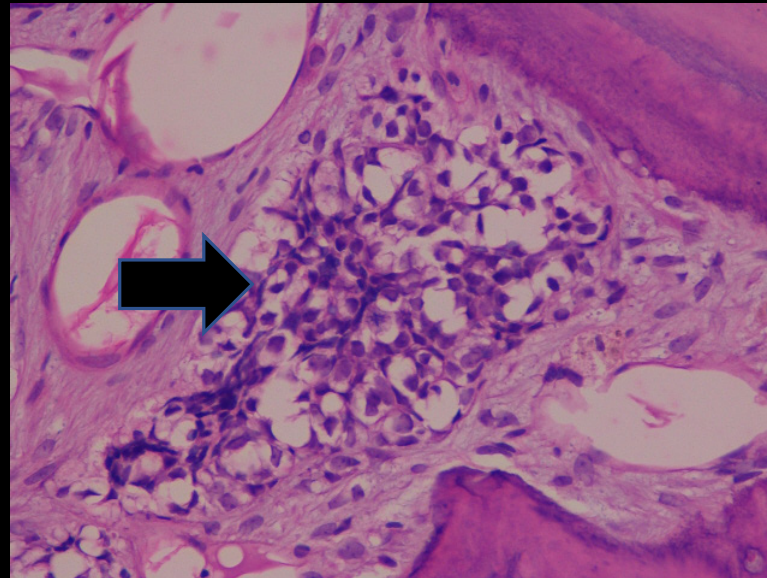
Bone marrow biopsy showed bony trabeculae, large areas of necrosis with focally preserved areas.

The preserved areas showed infiltration of marrow spaces by small round cells with hyperchromatic nuclei (black arrows).

Differential diagnosis for round cell tumor was considered.



H&E- 10 X



H&E- 40 X