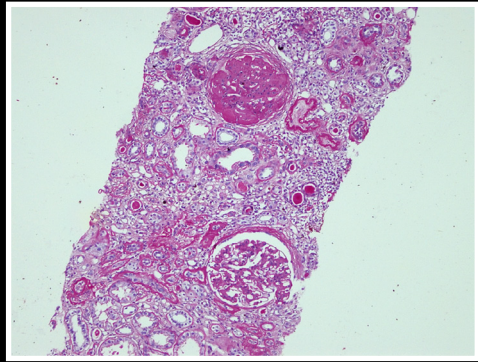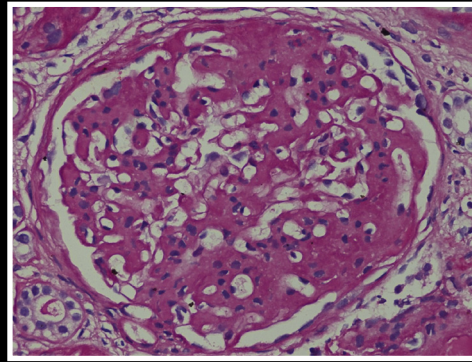
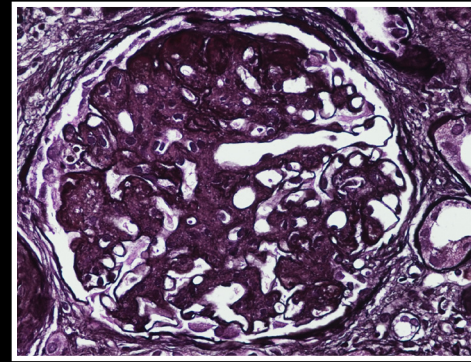


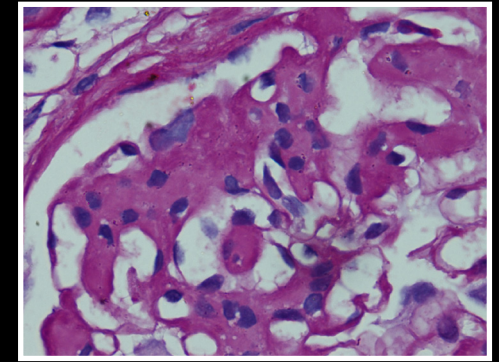
1A



1B

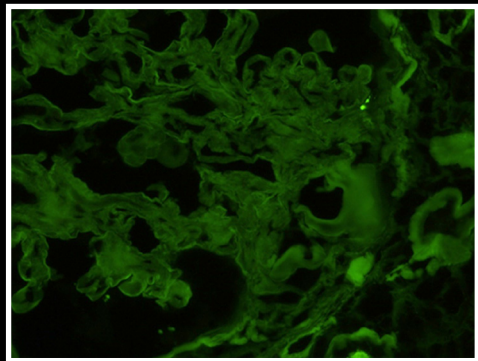


1C

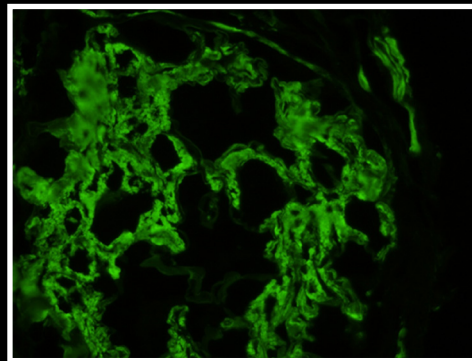


1D

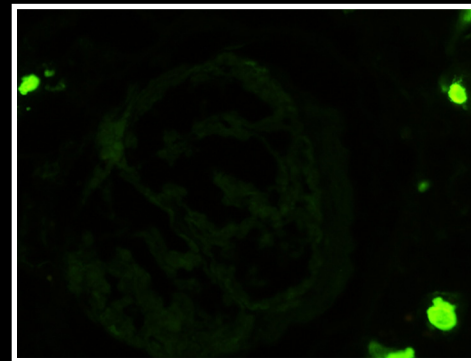
**Immunofluorescence (IF):** IF stained section reveal 6 glomeruli which show 3+ smudgy IgG staining in the glomeruli (Fig.2a). No definite granular or linear pattern of staining identified. Smudgy pattern of IgG staining is better highlighted at higher magnification. As compared to granular IgG staining in membranous glomerulopathy (Fig.2), the present case showed different pattern of positivity. IgG subclasses show only IgG4 subclass staining. Rest of the immunoglobulins (IgA, IgM) are negative. Kappa and Lambda light chain showed slightly more lambda staining than kappa, however no definite light chain restriction is seen (Fig.2C).



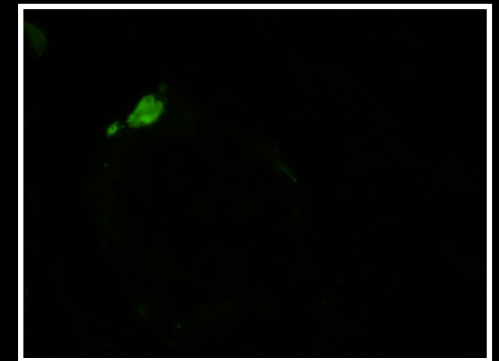
Albumin



IgG



IgA



IgM