

CASE 036

AUTHORS: Krati Agarwal, Lata Kini, Kunal Sharma

ACKNOWLEDGEMENT: Devender Kumar, Brijpal Singh Yadav, Teg Singh, Kamakhya Gogoi, Saurabh Singh

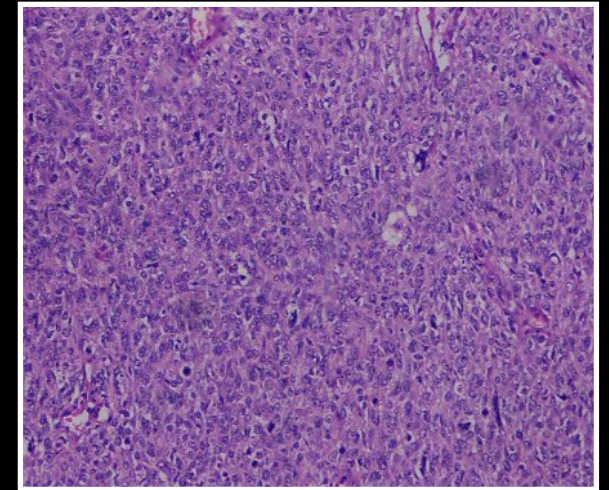
An eighteen year female presented with a bleeding, fungating mass in the right breast. Wide local excision specimen was sent for histopathological evaluation initially and later for immunohistochemical marker study.

GROSS DESCRIPTION

The mass was 9 cm in diameter with overlying ulcerated skin. Cut surface of the mass was firm, tan-white with areas of necrosis and hemorrhage.

HISTOMORPHOLOGY

Sections from breast mass showed tumour composed of sheets of spindled cells with few interspersed benign ducts and glands. The spindled cells showed moderate eosinophilic cytoplasm, elongated pleomorphic vesicular nuclei with conspicuous nucleoli. Mitosis was 5-6/ high power field. Areas of necrosis were also noted. On the basis of this histomorphology, differentials of sarcomatoid carcinoma, malignant phyllodes and primary sarcoma of breast were considered.



H&E