

CASE 035

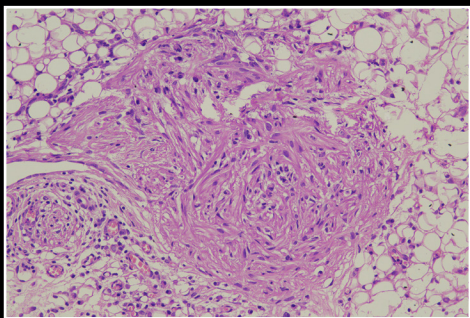
AUTHORS: Jaya Jain, Dipti Gupta, Kunal Sharma and Lata Kini

ACKNOWLEDGEMENT: Saurabh Singh, Brijpal Yadav

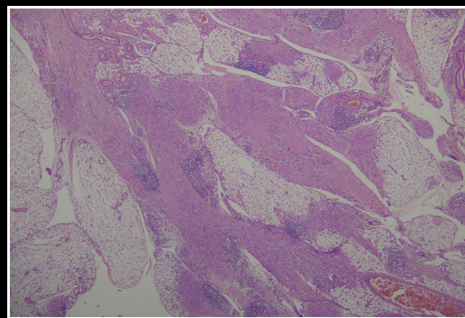
25 year female presented with pain in abdomen since 6 month. On USG a complex adenexal mass was seen in right adenexa. She underwent bilateral oophorectomy with omentectomy and right pelvic lymph node dissection. Histopathological evaluation done elsewhere was suggestive of mature teratoma of the right ovary. We received two blocks from omentum for IHC markers evaluation.

HISTOMORPHOLOGY

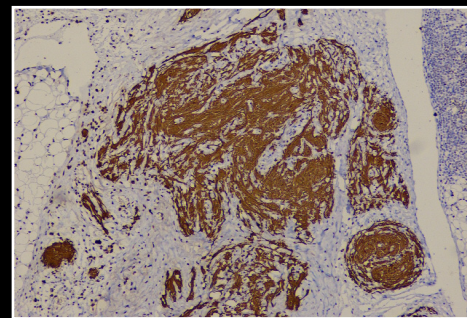
Sections from the omentum showed fibroadipose tissue with intermingling proliferation of ovoid to spindle shaped cells with fibrillary eosinophilic cytoplasm, elongated nuclei and inconspicuous nucleoli. Mitosis and necrosis were not seen.



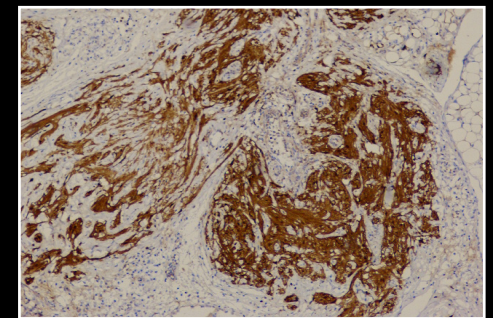
H&E 20X



H&E 4X



GFAP



S100