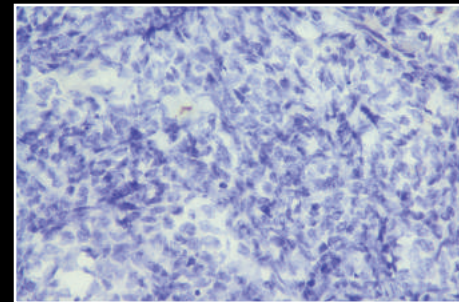
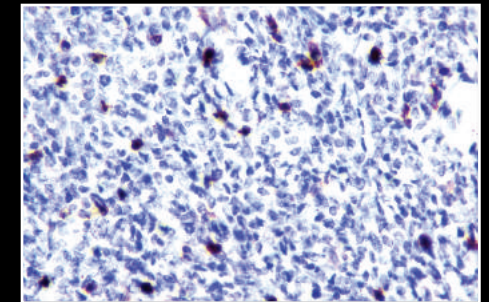


The most common site of involvement in the gastrointestinal tract is ileum. Myeloid sarcoma has no specific CT imaging feature and hence is indistinguishable from lymphoma and small round cell neoplasms like primitive neuroectodermal tumours on imaging alone. It can manifest as focal bowel wall thickening or polypoidal mass with intraluminal or exophytic components or both. A review of literature shows that myeloid sarcoma of the gastrointestinal tract has a high propensity for mesenteric, peritoneal and omental infiltration and perifocal discrete lymphadenopathy. Complications of this entity are intestinal obstruction, perforation and intussusception.⁸ Myeloid sarcoma can be found in patients with a wide spectrum of ages, with cases reported in individuals between 5 months and 89 years old. Despite this, the tumor mainly affects children and the younger population, with no clear gender preference.⁴

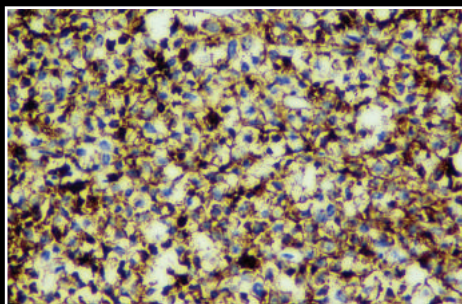
The five year cumulative incidence of isolated extramedullary relapse is 9%. About 40% to 47% of MS is misdiagnosed as lymphoma.^{5,10} Therefore an accurate diagnosis is important. A diagnosis of MS is established using pathologic features including infiltration of myeloblasts and strong myeloperoxidase (MPO) expression with negative cytokeratin immunohistochemical staining. These findings differentiate MS from lymphoma or other non-hematopoietic tumors.¹¹



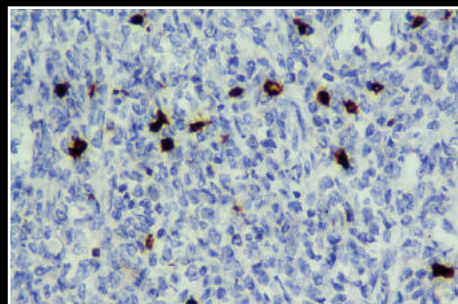
PANCK



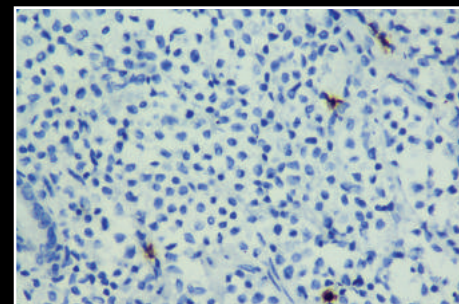
CD7



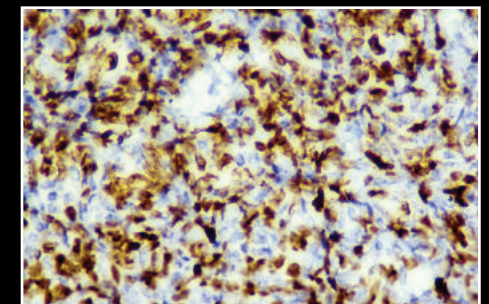
CD45



CD3



CD20



Ki67