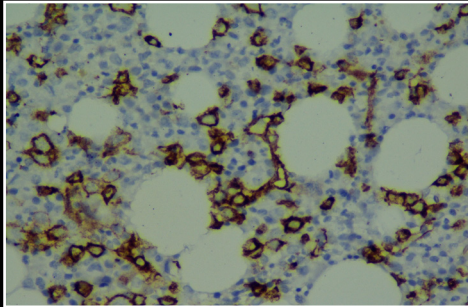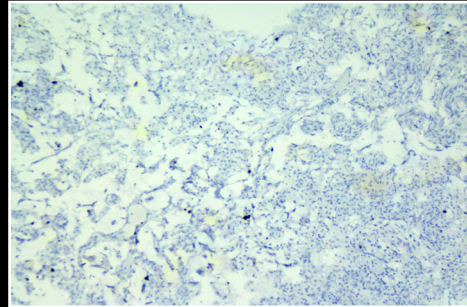
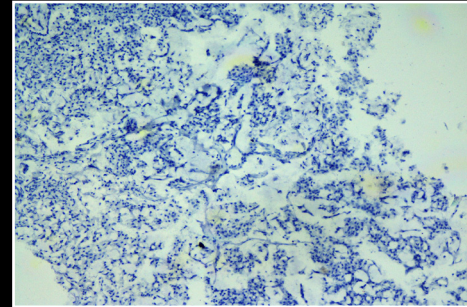


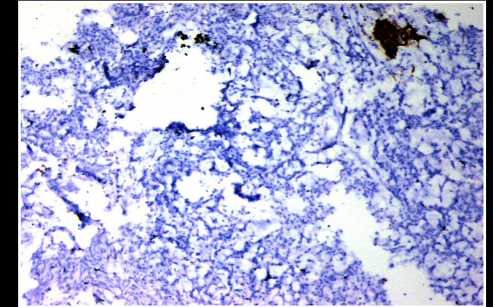
CD34



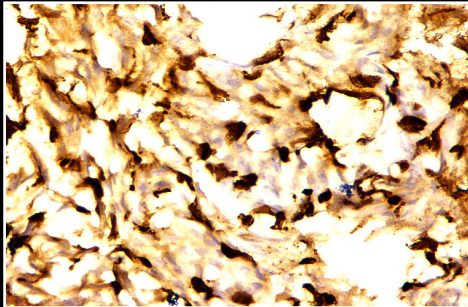
CK7



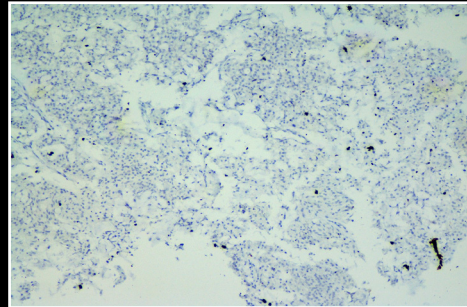
CK20



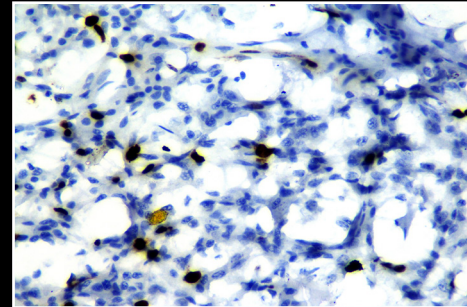
GFAP



Vimentin



OCT34



Ki67 5%

DIAGNOSIS

In view of the papillary architecture on morphology and characteristic immunopositivity for PanCK, a diagnosis of Papillary tumor of pineal region (PTPR), WHO grade II was proposed.

FOLLOW UP

The patient is presently receiving radiotherapy that would be followed by chemotherapy.