

CASE 020

AUTHORS: Aditi Dewan, MD, Ekta Jain, MD, DNB, Shipra Garg, MD, Sandeep Jasuja, DM, Shivani Sharma, DNB, DCP, Lata Kini, MD.

ACKNOWLEDGEMENT: Vandana Sharma

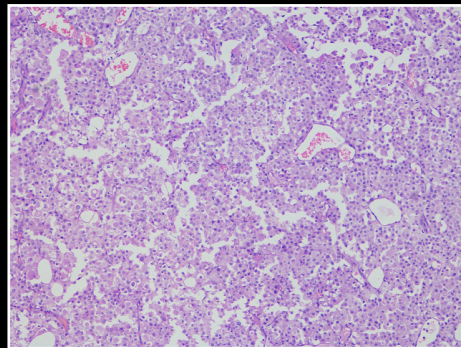
65 year old male with a urinary bladder mass.

CLINICAL HISTORY

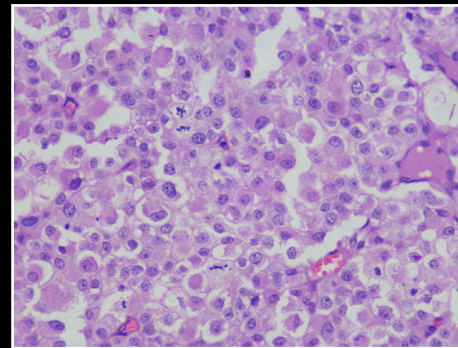
A 65-year old male patient presented to the outpatient department with complaints of lower abdominal pain and hematuria. Cystoscopy revealed ulceration of the entire bladder mucosa along with a thickened bladder wall. A transurethral resection of the bladder tumor (TURBT) was performed and submitted for histopathological examination.

PATHOLOGICAL FINDINGS

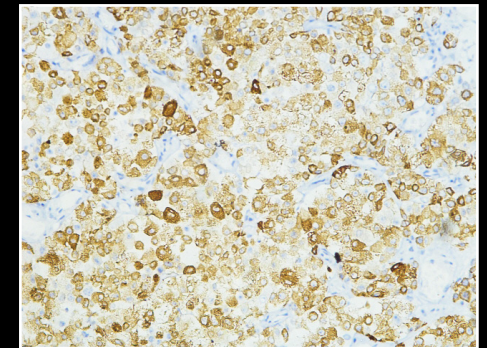
Gross: Multiple tan brown soft tissue pieces were received aggregating to less than 3ml. We received a single block for review and immunohistochemical analysis.



H&E 10X



H&E 40X



H&E 40X