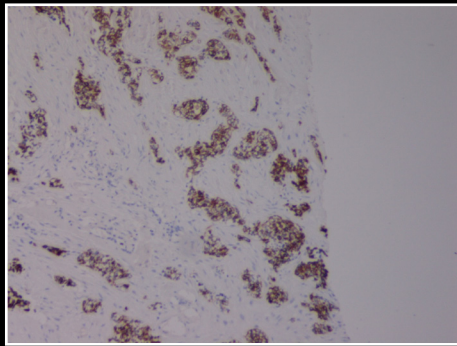
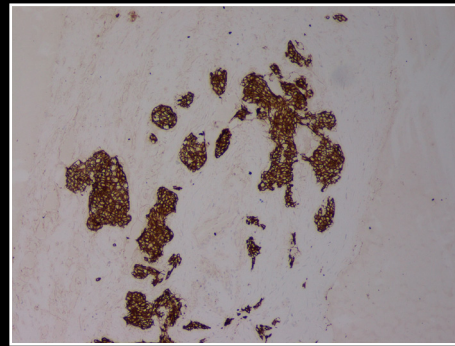


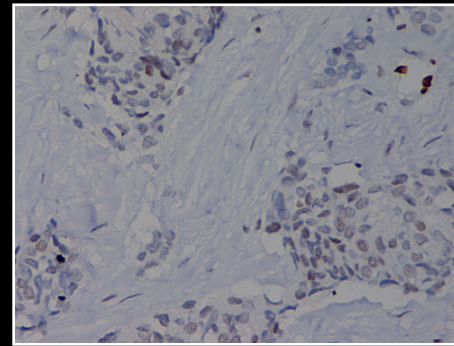
four cycles of chemotherapy following this diagnosis. Two years later, the patient developed multiple skin nodules. A core biopsy of the nodule was done and the paraffin block was received at CORE Diagnostics for review, immunohistochemistry and cytogenetics. Histomorphology revealed features of a small round cell tumour. Immunohistochemistry performed on the tissue revealed the tumor cells to be positive for CK7, Pan CK, FLI-1, and CD 99, and negative for CD56, CD 34, CD 45, and WT1.



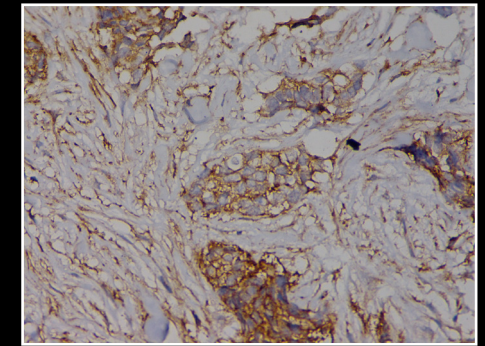
CK7



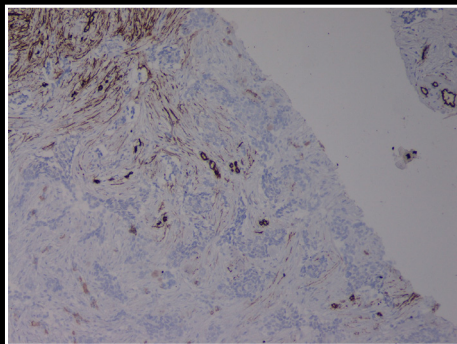
Pan CK



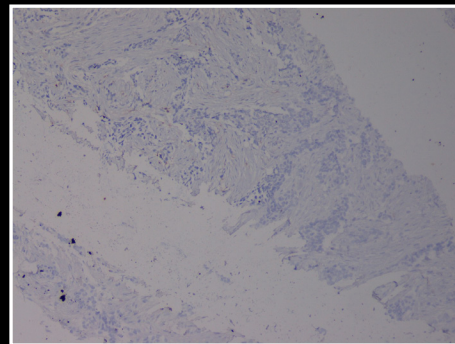
FLI-1



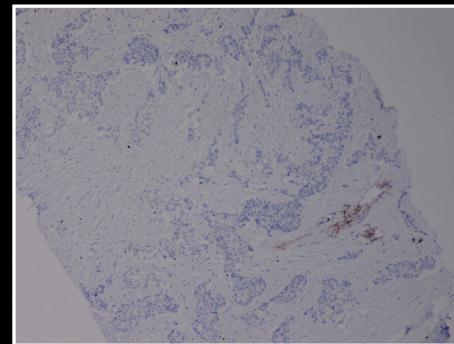
CD99



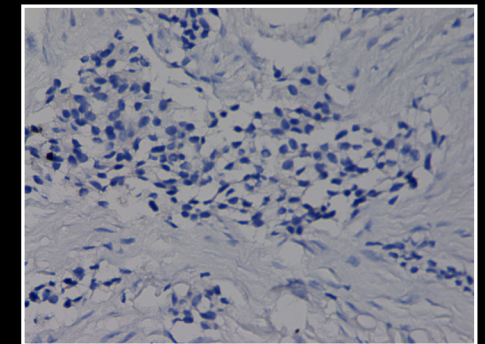
CD34



CD45



WT1



CD56