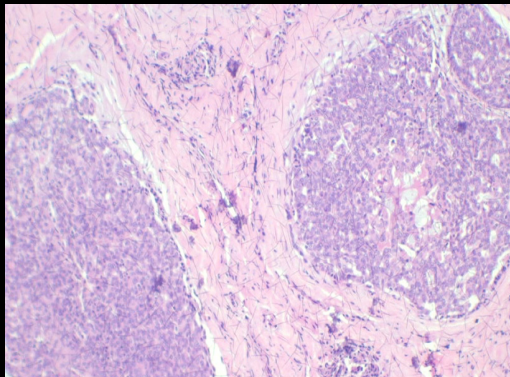
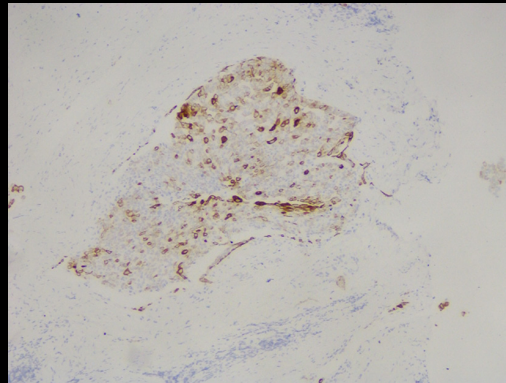


FINAL DIAGNOSIS:

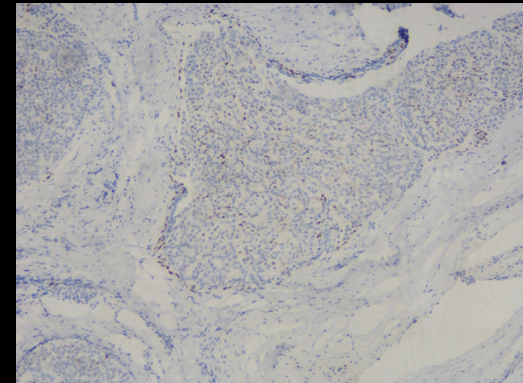
Salivary duct papilloma.



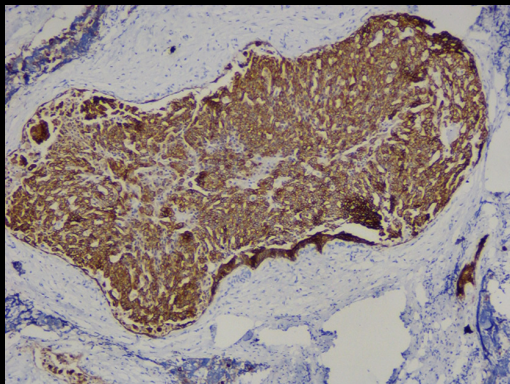
HEMATOXYLIN AND EOSIN (100X)



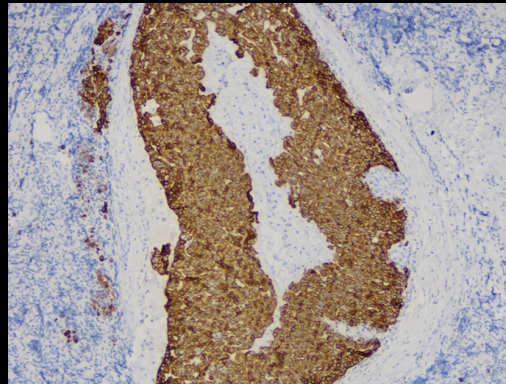
CK5/6



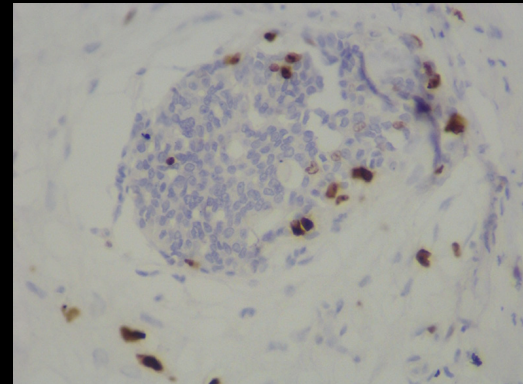
P63



CYTOKERATIN



CK7



Ki67