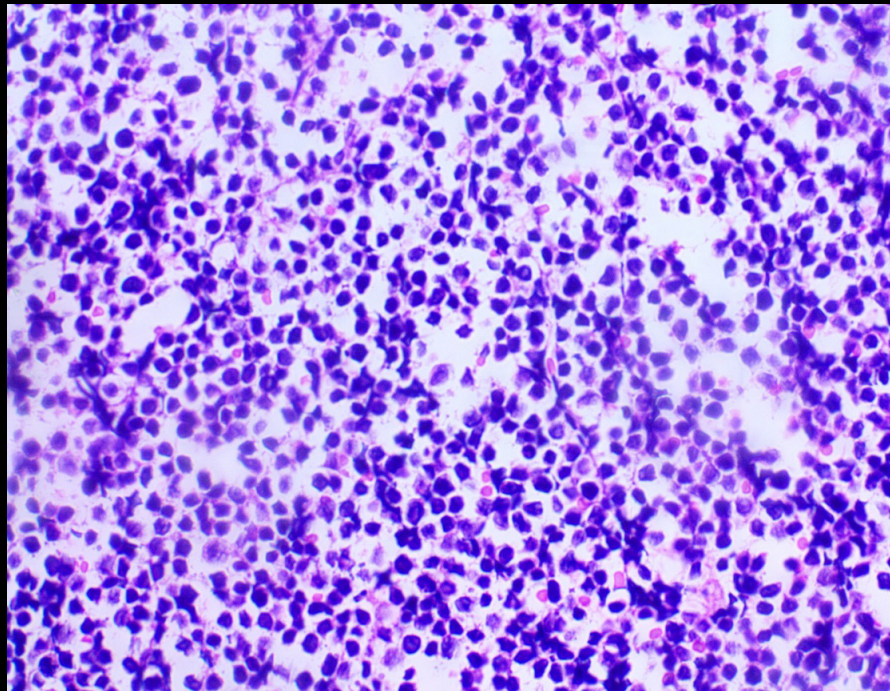


**BONE MARROW BIOPSY FINDINGS:** H&E- 10 X

Bone marrow trephine biopsy was hypercellular for age with overall cellularity of >95%. Hematopoietic elements of the marrow were diffusely replaced by sheets of atypical cells which were larger than lymphocytes, monomorphic in appearance, have round to oval nuclei, open chromatin & distinct nucleoli. There was near complete absence of erythroid precursors & myeloid precursors as well as megakaryocytes.



H&amp;E- 10 X