

CASE 041

AUTHORS: Neha Sabnis, Aditi Aggarwal, Aditi Dewan, Amit Bafna, Lata Kini

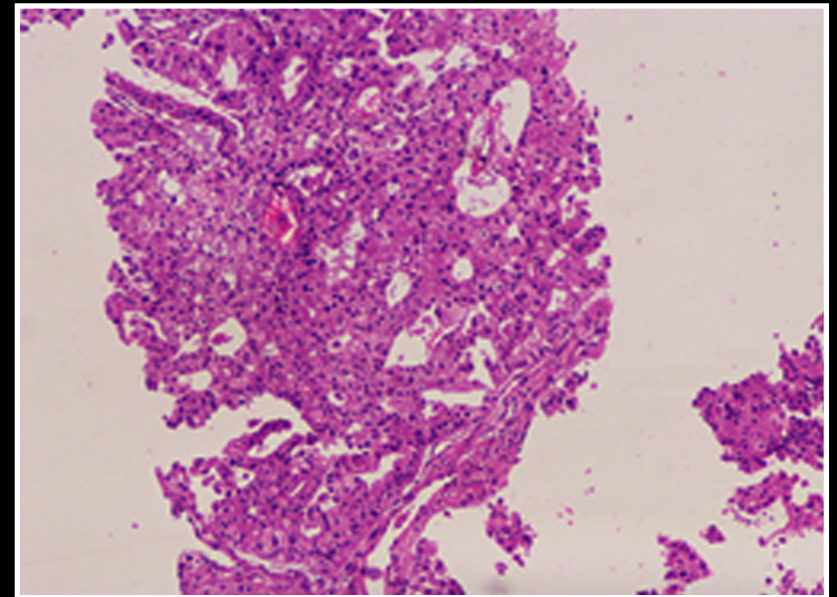
ACKNOWLEDGEMENTS: Saurabh Singh

A 63-year-old treatment naive female patient, presented with lung carcinoma. A USG guided biopsy specimen from the upper right lobe of the lung was sent for histological and molecular evaluation.

HISTOLOGICAL EVALUATION

H and E stained slide shows multiple linear cores showing diffuse infiltration by nests and glands lined by malignant epithelial cells displaying mild to moderate nuclear atypia, round hyperchromatic nuclei and abundant eosinophilic cytoplasm with cytoplasmic vacuolation at places. Overall morphological features were those of an adenocarcinoma. The tumor content of the biopsy was evaluated as >80%.

The biopsy specimen was then sent for an extended lung cancer panel by NGS for molecular evaluation, to decide the eligibility of the patient for targeted therapy.



H&E