

# CASE 028

**AUTHORS:** Aditi Dewan, MD, Vishwesh Rajawat, MD, Shivani Sharma, DNB, DCP Ekta Jain, MD, DNB, Kunal Sharma, DNB, Lata Kini, MD

**ACKNOWLEDGEMENT:** Munmun Bhattacharya, Brijpal Singh Yadav, Vijendra Bhandari, Arjun Singh Rana

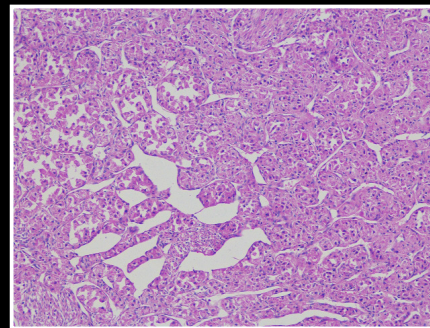
**Oncocytic variant of Glomus tumor: A diagnostic dilemma.**

## CLINICAL HISTORY

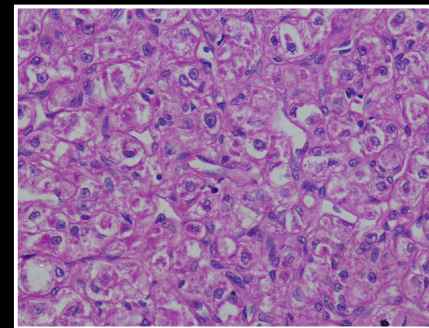
A 32-year old female patient presented to the outpatient department with complaints of abdominal pain and a palpable lump per abdomen since one year. The patient was pregnant at the time and only underwent surgery post partum. Ultrasonography showed presence of a solid hypoechoic extraperitoneal vascular nodule in the right hypochondrium within the muscle layer, indenting the bowel loops and bulging into the abdominal cavity, that measured 4.5x 4.2x 3.6 cms in size. Underlying liver was unremarkable.

## PATHOLOGICAL FINDINGS

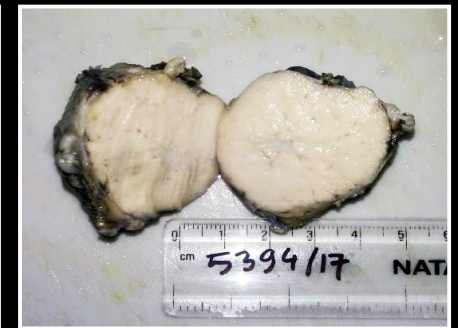**Gross:** On gross examination the excision specimen was a well circumscribed non encapsulated nodule measuring 5.0x4.0x3.5 cm with a tan white firm cut surface.



H&E 10X



H&E 40X



H&E 40X