

CASE 010

Authors: Dr. Sambit K. Mohanty, MD, DNB, FRCPath, Dr. Shivani Sharma, DCP, DNB, FRCPath-1, Dr. Anurag Sharma, MD, Dr. Samriti Arora, MD, Dr. Lata Kini, MD

Acknowledgement: Vijender Bhandari, DMLT and Vipin Chauhan, DMLT

Long-standing exophytic mass in the right infratemporal region in an 80-year-old woman.

CLINICAL HISTORY AND IMAGING FINDINGS

An 80-year-old woman presented with a long-standing exophytic mass in the right temple region. The mass had been increasing in size slowly and progressively over the last 8 years. There was no history of pain or bleeding. She had no family history of cancer. On physical examination, the mass was 5 cm in maximum dimension, lobulated, and was tan-pink to red in color. It was soft to firm in consistency and was non-tender. On investigation, the mammogram, chest computed tomography, colonoscopy, and upper gastrointestinal endoscopy were within normal limits. A positron emission tomography (PET)-computed tomography to look for metastatic disease was performed; however, it did not show any PET-positive focus.

PATHOLOGIC FEATURES

A sentinel lymph node biopsy was not considered in this case. After excision of the mass, the specimen was submitted for histopathologic examination. It was exophytic, tan-pink to red, friable, and measured 5.9 x 3.3 x 1.3 cm. Histopathologic examination showed exophytic as well as endophytic growth pattern with papillary and cystic areas; prominent decapitation

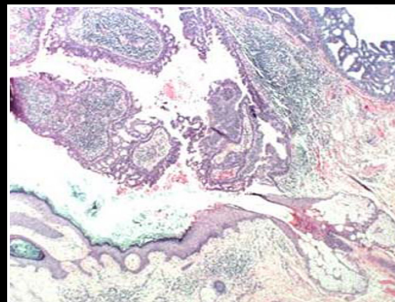


Figure 1A

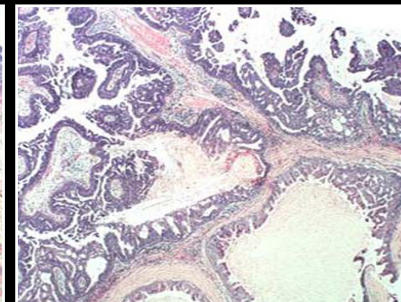


Figure 1B

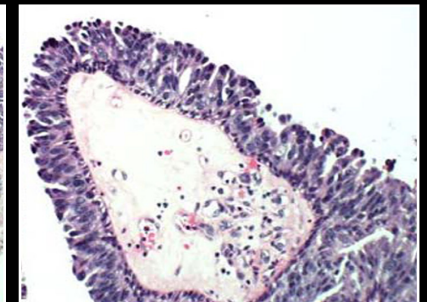


Figure 1C