

synaptophysin (SYN) in variable degrees (multifocal to diffuse) and intensity (moderate to strong), while the epithelial markers (pancytokeratin [panCK], epithelial membrane antigen, high molecular weight cytokeratin, and cytokeratin 5/6), CD34, myoepithelial markers (smooth muscle actin and p63) and mammary lineage-associated markers (GATA3, mammaglobin, and gross cystic disease fluid protein-15 [GCDFP-15]) were negative in the tumor (Figures 2 and 3). The Ki-67 labeling index was 50%. A fluorescence in situ hybridization (FISH) was performed to detect a rearrangement of the EWSR1 locus, using the LSI EWSR1 dual-color, break-apart probe according to the manufacturer's recommendations. No rearrangement involving the EWSR1 locus was detected (Figure 4). Prognostic markers, including estrogen and progesterone receptors, Her-2/neu, isocitrate dehydrogenase, and ERG were negative. A whole body imaging by PET-CT scan was within normal limit.

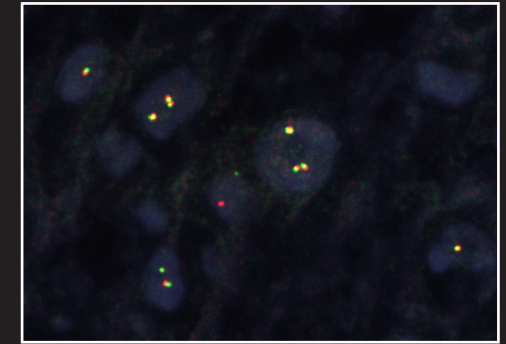


Figure 4

FINAL DIAGNOSIS

Primary extraskeletal myxoid chondrosarcoma of the breast.

DISCUSSION

Extraskeletal myxoid chondrosarcoma (EMC) is a unique and distinct soft tissue neoplasm with classical histomorphology and divergent growth pattern, such as chondroid and neurogenic differentiation. It was first described by Stout and Verner¹. Enzinger and Shiraki (1972) described a series of 34 cases of chondroblastic tumors that arise from extraskeletal soft tissues². Over the years, EMC has been confirmed to be a unique soft tissue sarcoma that has a distinctive t(9;22) chromosomal translocation associated with it³. EMC comprises less than 3% of all soft tissue sarcomas⁴. These tumors have a male preponderance (M:F ratio 2:1) and generally occur in the 5th to 6th decades of life, although rare cases have been reported in children. They are most commonly located in the extremities, limb girdles, or trunk⁵. Since its original description, EMC has been reported in unusual locations, including the nasal cavity, the central nervous system and the vulva amongst other sites⁶⁻¹². While secondary myxoid chondrosarcomas of breast have been reported, so far as primary EMC is concerned, there is no description of this entity in the literature. The index case is the first reported case in the literature.

The exact pathogenesis of EMC is unclear, however, there is recent evidence that suggests these tumors arise from a primitive mesenchymal cell with a propensity for multidirectional differentiation¹³. The original hypothesis that this tumor represents a variant of chondrosarcoma has been challenged in the recent years. The absence of true cartilage formation, the presence of a myxoid matrix that is rich in mucin and poor in collagen II and aggrecan core protein, as well as the presence of neurosecretory granules, microtubule associated protein-2, and beta tubulin