

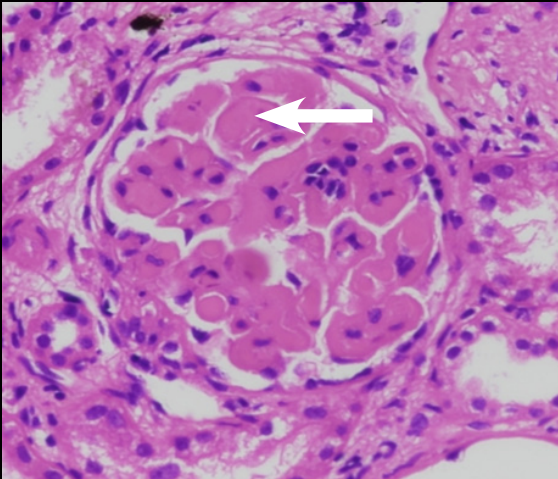Fig. 1 H&E, Diffuse capillary wall thickening with Intracapillary plugs

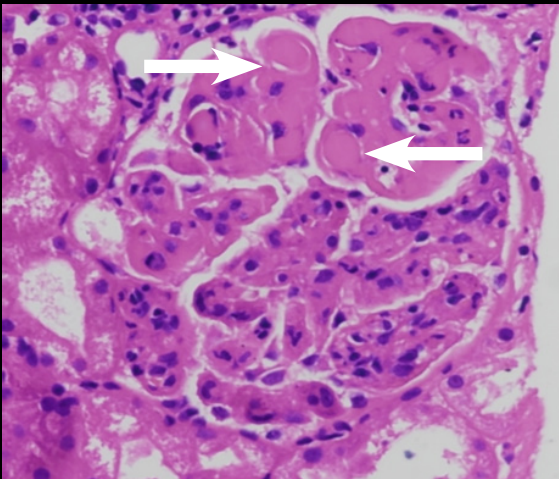


Fig. 2 H&E, Diffuse capillary wall thickening with Intracapillary plugs

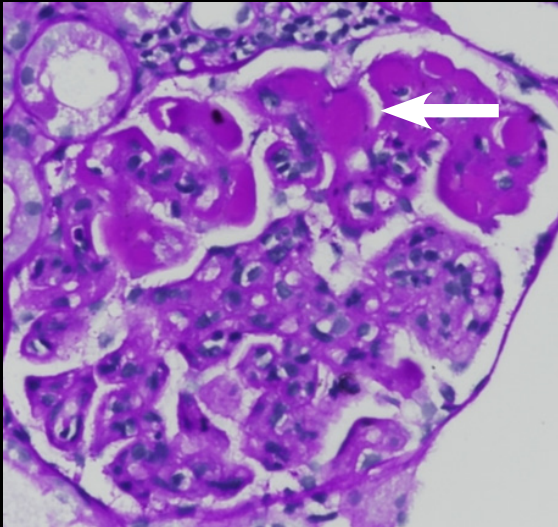


Fig. 3 Intracapillary plugs are visible as PAS-positive material

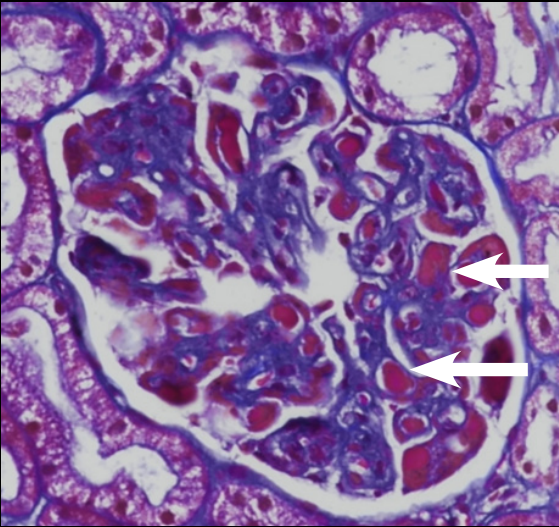


Fig. 4 Trichrome stain, Intracapillary plugs, bright red (arrow)

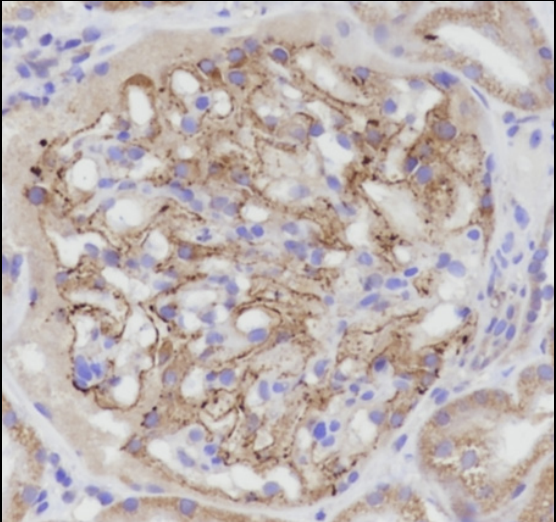


Fig. 5 IHC: PLA2R: Granular positivity along capillary loops